

Imaging of Cholangiocarcinoma – Research Update 2018

AMMF Conference/Information Day, May 10 2018

R.R.A. Syms^{1*}, I.R. Young¹, E. Kardoulaki¹,
S. Taylor-Robinson², C. Wadsworth³,
N. Chamadol⁴, W. Boonpongsathain⁴, N. Kuntikeo⁵
S. Zhang⁶

¹EEE Dept., South Kensington Campus, Imperial College London

²Dept. of Medicine, St. Mary's Hospital Campus, Imperial College London

³Hammersmith Hospital, Imperial College NHS Trust

⁴Dept. of Radiology, Khon Kaen University, Khon Kaen, Thailand

⁵Dept. of Surgery, Khon Kaen University, Khon Kaen, Thailand

⁶Philips Healthcare, Singapore

*TEL +44 207 594 6203; email r.syms@imperial.ac.uk

Acknowledgements: Sponsors



EPSRC

Engineering and Physical Sciences
Research Council

welcometrust

- All have supported this work, twice; they have our thanks.

Global Program: Partners



St Mary's Hospital
Hepatology, Endoscopy, Imaging



EEE Dept., ICL
Engineering, MRI



Khon Kaen University Hospital
Surgery, Imaging, Pathology, Parasitology
CASCAP

Global Program: People



Prof. Simon
Taylor-Robinson
Hepatology



Dr Chris
Wadsworth
Endoscopy



Dr Marc
Rea
Imaging



Warren
Casperz
Imaging



Prof. Ian
Young
MRI



Dr Evi
Kardoulaki
Engineering



Dr Munir
Ahmad
Engineering



Dr Khoonsake
Segkoonthod
Engineering



Prof. Narong
Khuntikeo
Surgery



Prof. Nittaya
Chamadol
Imaging

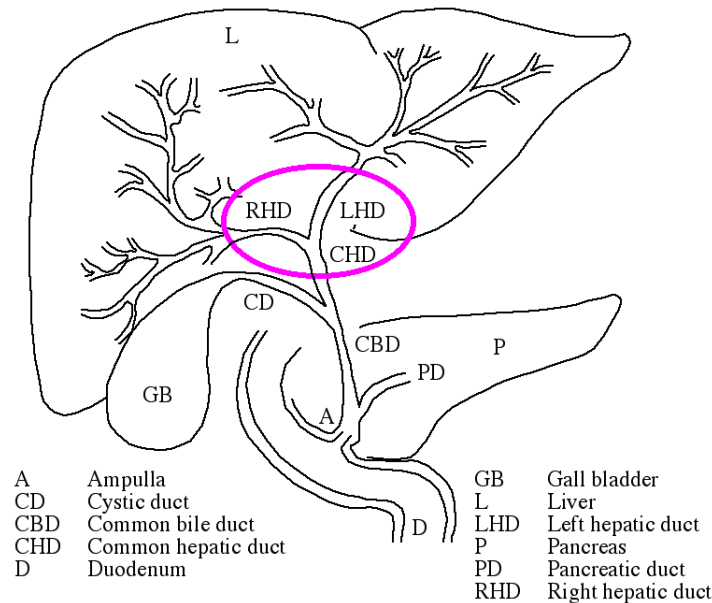


Wuttisuk
Boonsongpathain
MRI



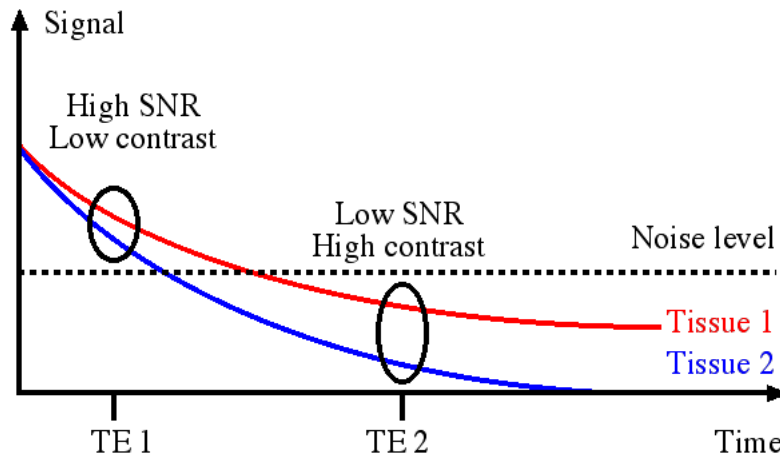
Prof. Paiboon
Sithithaworn
Parasitology

MRI: Goal




- Better imaging near the hilar region of the liver ductal system
 - Could lead to improved planning of complex resection operations
- But what is meant by ‘better’?

MRI: Image Contrast



Queen's Tower, ICL



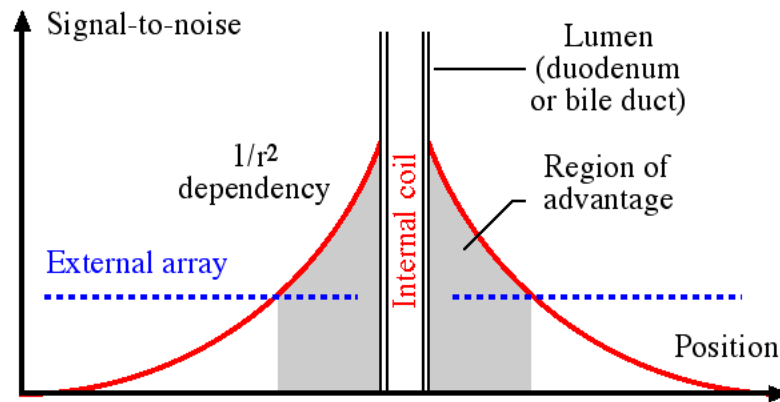
High signal
Low contrast



Lower signal
Higher contrast

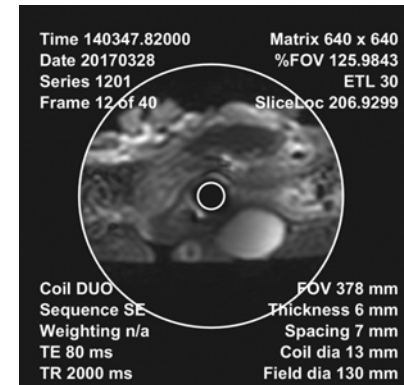
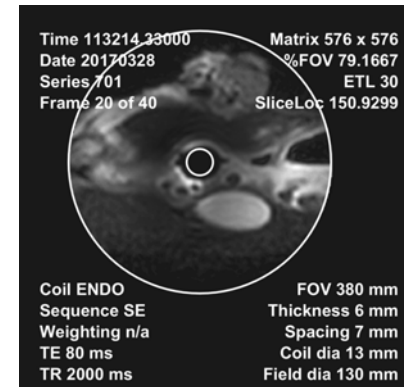
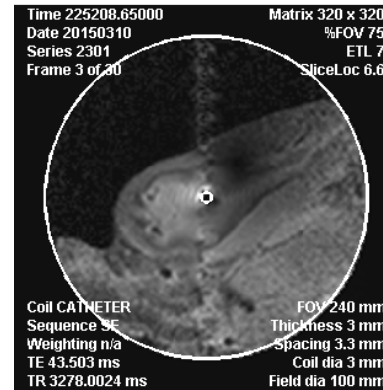
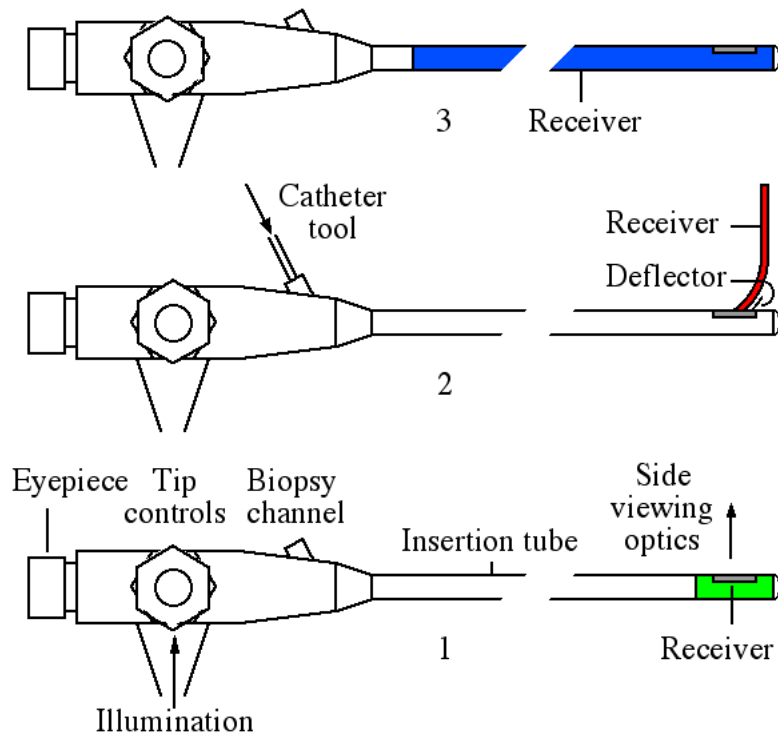
- MRI requires detection of radio frequency signals
 - Different signal decay times generate contrast between tissue types
 - High contrast obtained by waiting longer; signals then generally lower

MRI: Internal Coils



- Field-of-view of external coil array designed to be large
 - Signal detected from whole abdomen, but also noise
- Field-of-view of internal coil is much smaller
 - Reduced detection of body noise
 - Improved imaging out to fixed radius (but needs image correction)
 - Can introduce coil into the duodenum or bile duct

Internal MRI



- All operating at KKUH

Off to Thailand



- Khon Kaen, Isaan Province

Off to Thailand



- UK Team: Evi Kardoulaki, Chris Wadsworth, Richard Syms

Off to Thailand



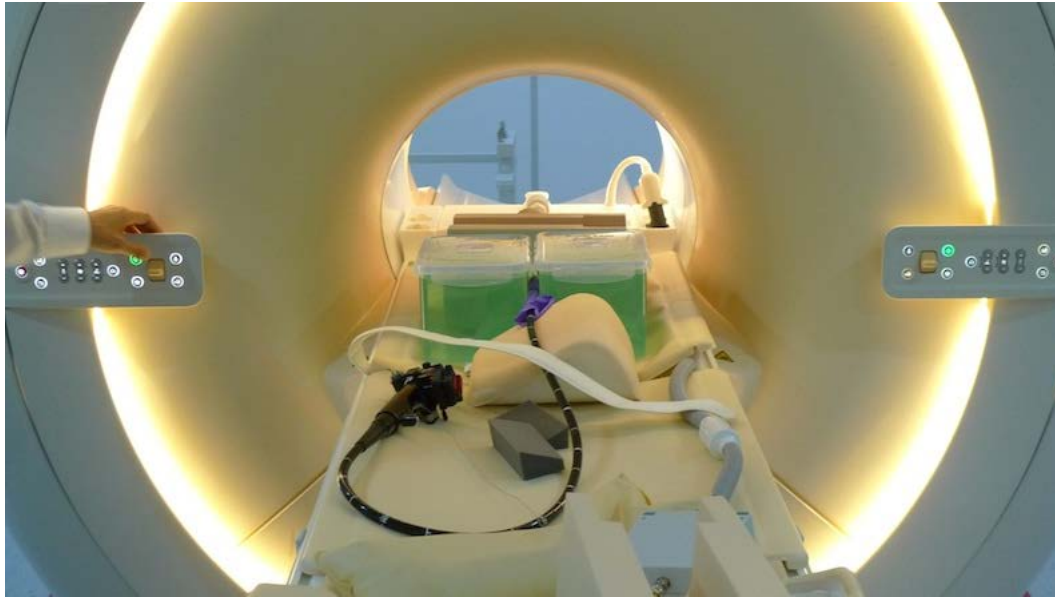
- At CASCAP with Narong, Nittaya, Paiboon and Puangrat

Off to Thailand



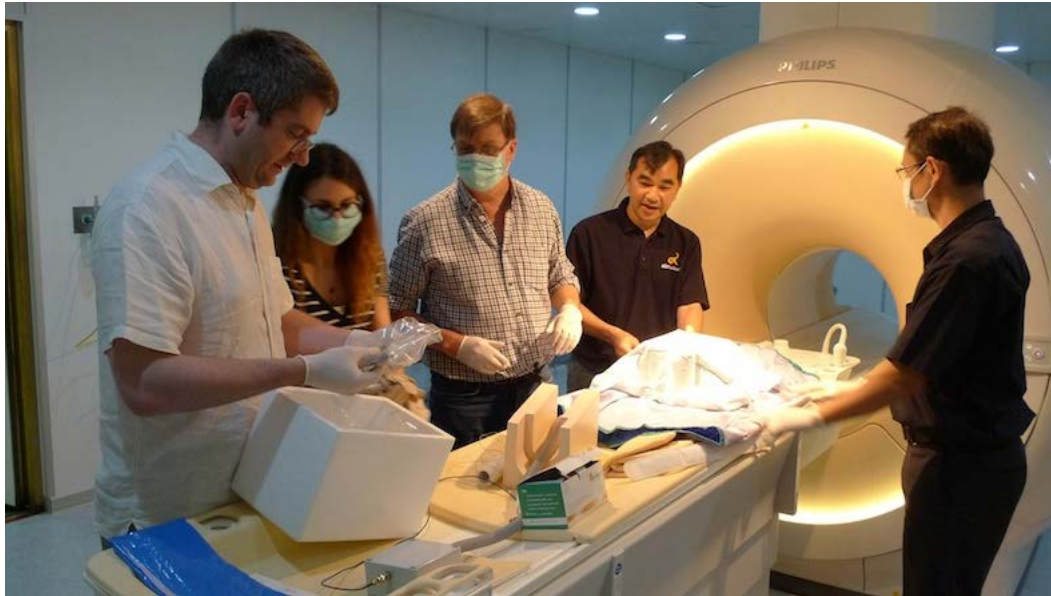- MRI Centre at Khon Kaen University Hospital

Preparatory Work



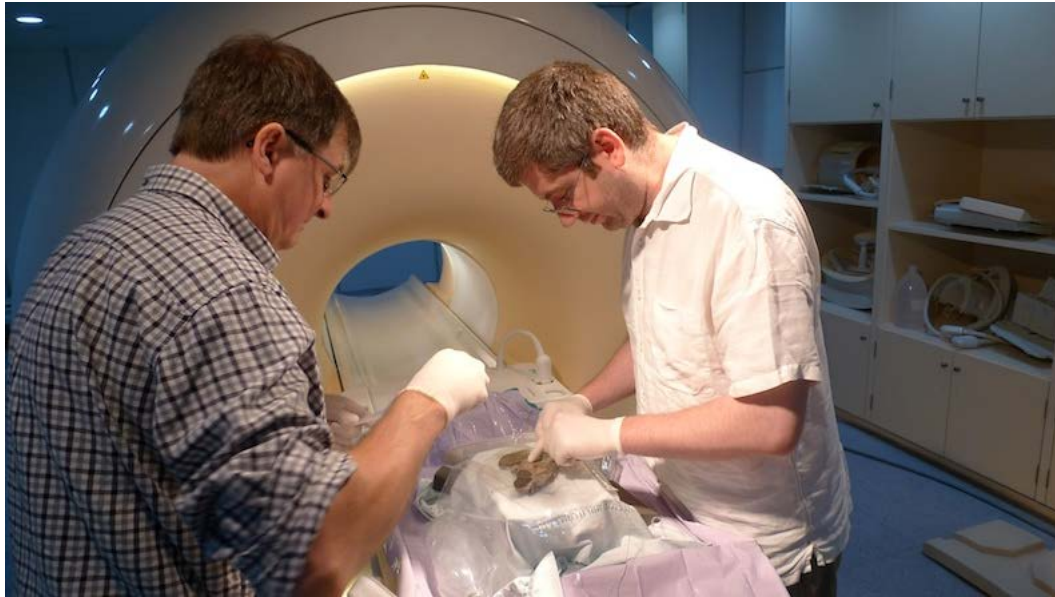- A lot of equipment to get working, in a hurry

Imaging Experiments



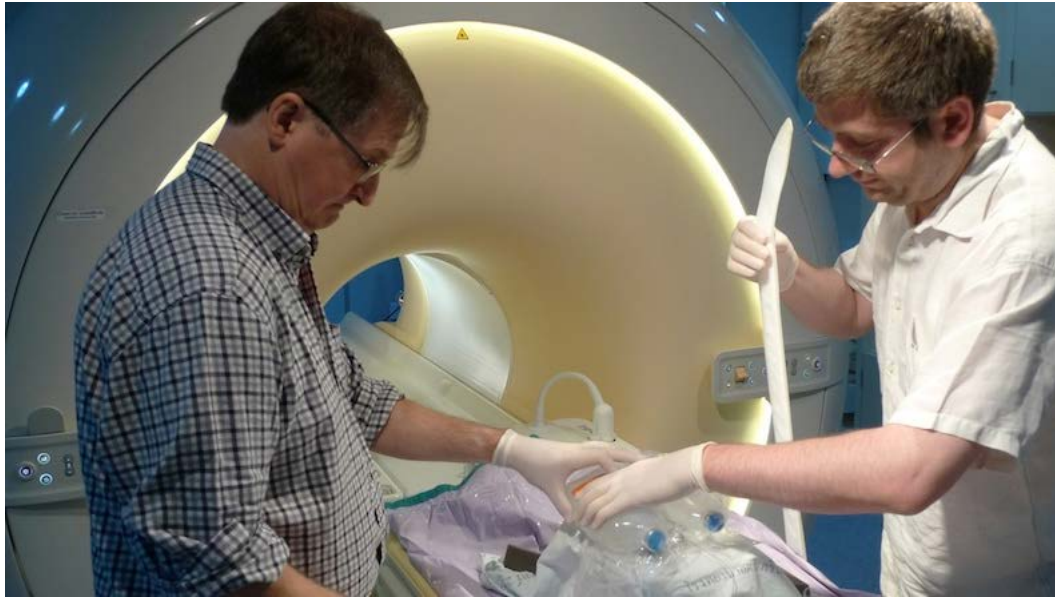- Selecting resection specimens

Imaging Experiments



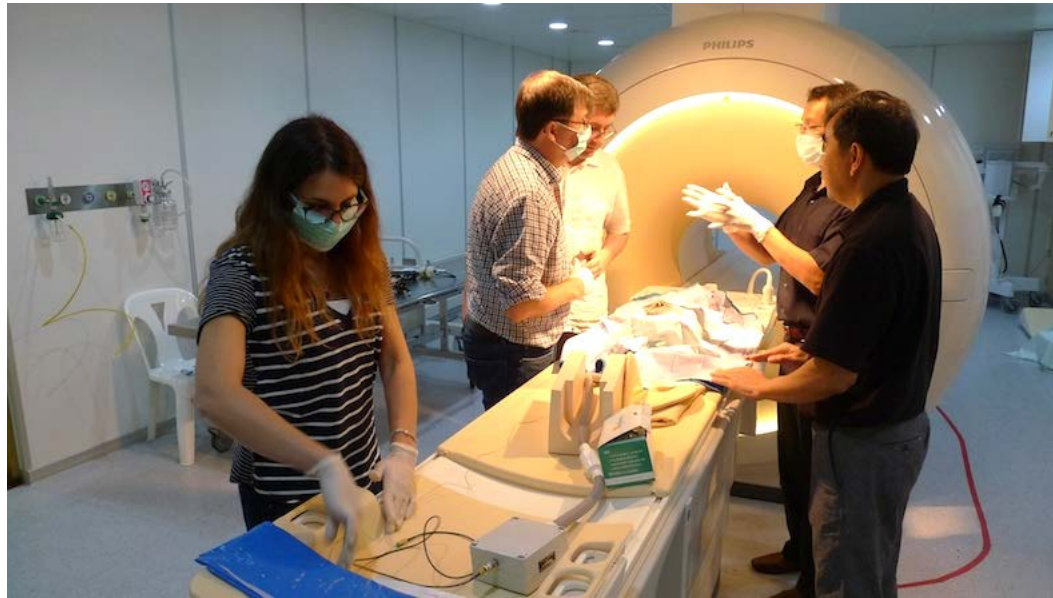- Placing a specimen

Imaging Experiments



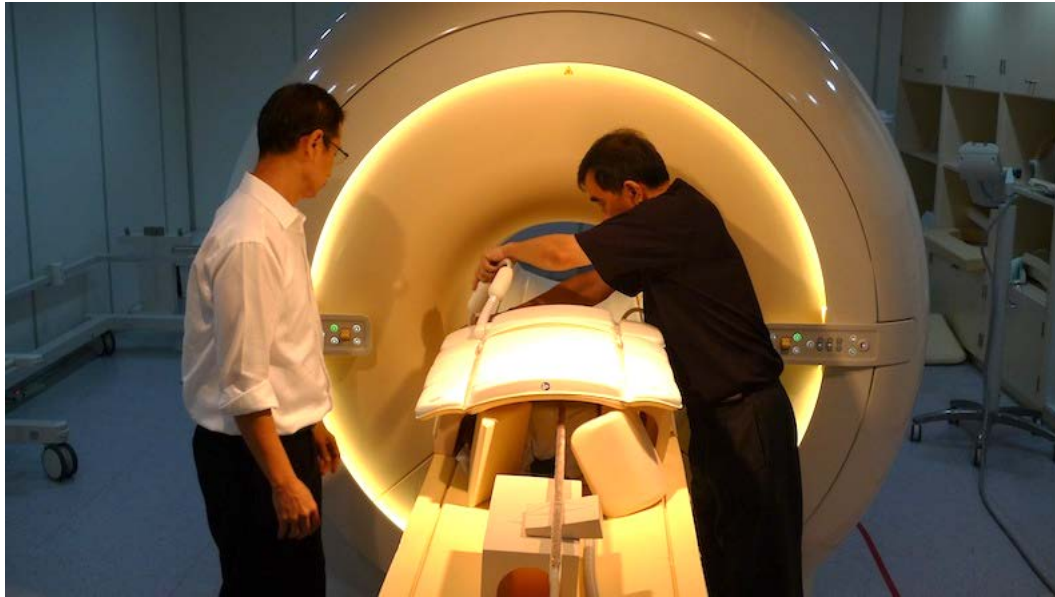
- Adding loading for realism

Imaging Experiments



- Connecting the new interface

Imaging Experiments



- Adding the torso coil

Imaging Experiments



- Working on the scanner protocol

Conclusions

- *In vivo* use still unproven
 - Results will be worse due to anatomy, patient motion, perfusion
- *In vivo* use may be impractical
 - Costly, time consuming procedure
 - Access may be restricted by blocked ducts
- But
 - We have definitely seen something

Imaging Team Photo



- Clearly growing!

Thanks to:

- Our Thai hosts, gracious as ever:
 - Narong
 - Nittaya
 - Paiboon
 - Puangrat
 - Watcharin
 - Attapol
 - Mr Wutti
- Anonymous Thai patients
- And all at CASCAP